


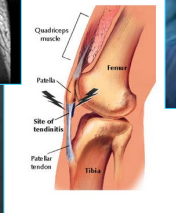

HOW I REPAIR AN ACUTE PATELLAR TENDON RUPTURE

S. ZAFFAGNINI
G.M. MARCHEGGIANI MUCCIOLI, T. BONANZINGA, A. GRASSI,
M. MARCACCI

III CLINICA ORTOPEDICA e LAB. BIOMECCANICA
 Dir. Prof. M. Marcacci
 UNIVERSITY OF BOLOGNA
 ISTITUTO ORTOPEDICO RIZZOLI, ITALY


SERVIZIO SANITARIO REGIONALE
 EMILIA-ROMAGNA
 Istituto Ortopedico Rizzoli di Bologna
 Istituto di Ricovero e Cura a Carattere Scientifico

PATELLAR TENDON RUPTURE

SERVIZIO SANITARIO REGIONALE
 EMILIA-ROMAGNA
 Istituto Ortopedico Rizzoli di Bologna
 Istituto di Ricovero e Cura a Carattere Scientifico

PATELLAR TENDON RUPTURE



**SERIOUS INJURY REQUIRING
 PROMPT DIAGNOSIS AND
 TREATMENT**

**DELAYED SURGERY AFFECT
 THE FINAL RESULTS**

Lohwe 1994
 Greis 2005

SERVIZIO SANITARIO REGIONALE
 EMILIA-ROMAGNA
 Istituto Ortopedico Rizzoli di Bologna
 Istituto di Ricovero e Cura a Carattere Scientifico

PATELLAR TENDON RUPTURE

**QUADRICEPS
> 40 Y.**

**HIGH-ENERGY TRAUMA
 OR CUMULATIVE
 MICROTRAUMA**

**PATELLAR
< 40 Y.**

Kannus 1991

SERVIZIO SANITARIO REGIONALE
 EMILIA-ROMAGNA
 Istituto Ortopedico Rizzoli di Bologna
 Istituto di Ricovero e Cura a Carattere Scientifico

PATELLAR TENDON RUPTURE

891 BIOPSY SPECIMENS

**100% OF RUPTURED TENDONS SHOWED
 HYSTOPATHOLOGICAL CHANGES**

VS

34% IN CONTROL GROUP

Kannus 1991

**ONLY DEGENERATED TENDONS WOULD
 RUPTURE**

McMaster 1933
 Siwek 1981
 Ramseier 2006

SERVIZIO SANITARIO REGIONALE
 EMILIA-ROMAGNA
 Istituto Ortopedico Rizzoli di Bologna
 Istituto di Ricovero e Cura a Carattere Scientifico

PATELLAR TENDON RUPTURE

ASSOCIATED TO SYSTEMIC DISEASE

- ✓ LES
- ✓ RHEUMATHOID ARTHRITIS
- ✓ CHRONIC RENAL FAILURE
- ✓ DIABETES
- ✓ GOUT
- ✓ HYPERTHYROIDISM
- ✓ HYPERCALCEMIA
- ✓ STEROID INJECTIONS
- ✓ (PREVIOUS HARVESTING)



Ismail 1969 Webb 1986
 Carbon 1994 Greis 2005
 Matava 1996

SERVIZIO SANITARIO REGIONALE
 EMILIA-ROMAGNA
 Istituto Ortopedico Rizzoli di Bologna
 Istituto di Ricovero e Cura a Carattere Scientifico

PATELLAR TENDON RUPTURE OCCURS

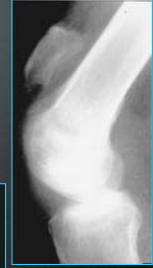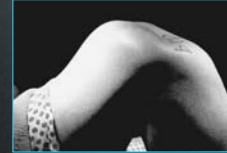- ✓ **PATELLAR BONE TENDON JUNCTION / INFERIOR POLE PATELLAR FRACTURE**
- ✓ **MIDSUBSTANCE (laceration)**
- ✓ **AVULSION FRACTURE OF THE TIBIAL TUBEROSITY (children)**

SERVIZIO SANITARIO REGIONALE
EMILIA-ROMBAGNOLA
Istituto Oncologico Pascale di Bologna
Istituto di Ricovero e Cura a Carattere Scientifico



DIAGNOSIS

- ✓ **HISTORY**
- ✓ **SWELLING AND PAIN**
- ✓ **GAP IN THE TENDON (US)**
- ✓ **ACTIVE KNEE EXTENSION WEAKNESS**
- ✓ **PATELLA ALTA AT LATERAL X-Ray**

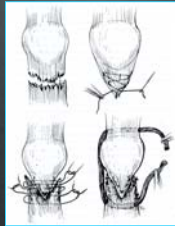


SERVIZIO SANITARIO REGIONALE
EMILIA-ROMBAGNOLA
Istituto Oncologico Pascale di Bologna
Istituto di Ricovero e Cura a Carattere Scientifico



ACUTE SURGICAL REPAIR

**AUGMENTATION WITH MERSILENE or ARTIFICIAL LIG.
OLD TECHNIQUES**



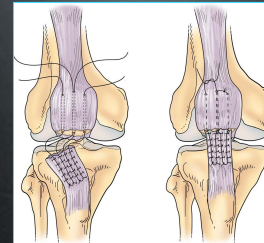
Levin 1976
Miskew 1980
Kelly 1984
Fujikawa 1994

SERVIZIO SANITARIO REGIONALE
EMILIA-ROMBAGNOLA
Istituto Oncologico Pascale di Bologna
Istituto di Ricovero e Cura a Carattere Scientifico



ACUTE SURGICAL REPAIR

INTO A BONY THROUGH WHEN THE RUPTURE OCCURS AT THE OSTEOTENDINOSUS JUNCTION



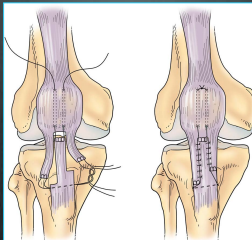
Scott 1994
Ong 2000

SERVIZIO SANITARIO REGIONALE
EMILIA-ROMBAGNOLA
Istituto Oncologico Pascale di Bologna
Istituto di Ricovero e Cura a Carattere Scientifico



ACUTE SURGICAL REPAIR

WITH RUNNING INTERLOCKING SUTURES WHEN THE RUPTURE OCCURS WITHIN THE SUBSTANCE OF THE TENDON



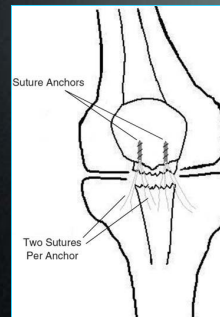
Scott 1994

SERVIZIO SANITARIO REGIONALE
EMILIA-ROMBAGNOLA
Istituto Oncologico Pascale di Bologna
Istituto di Ricovero e Cura a Carattere Scientifico



ACUTE SURGICAL REPAIR

NEW TECHNIQUE: REPAIR USING SUTURE ANCHORS



21% REPORTED FAILURES at 29-month MEAN FOLLOW-UP

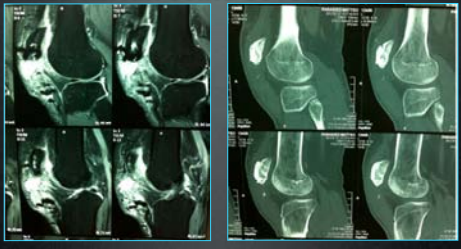
Bushnell 2006
Bushnell 2008

SERVIZIO SANITARIO REGIONALE
EMILIA-ROMBAGNOLA
Istituto Oncologico Pascale di Bologna
Istituto di Ricovero e Cura a Carattere Scientifico



CASE REPORT: 20 YEARS OLD PROFESSIONAL BASKET PLAYER, weight 100 Kg, height 1.98 m

FAILED REPAIR USING SUTURE ANCHORS



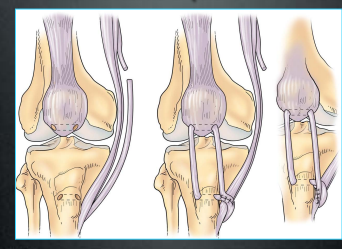
DIFFICULT MANAGEMENT (ANCHORS ARE DIFFICULT TO REMOVE, HIGH RISK OF PATELLAR FRACTURE, POSSIBLE INFECTION IN CASE OF SKIN TEAR BY PULLED-OUT ANCHORS)

SERVIZIO SANITARIO REGIONALE EMILIA-ROMAGNA Istituto Oncologico Pascale di Bologna Istituto di Ricovero e Cura a Carattere Scientifico

ACUTE SURGICAL REPAIR

IN CASE OF INADEQUATE TISSUE

1) AUGMENTATION WITH AUTOGENOUS TISSUE: HAMSTRINGS (ST or GR + ST)




*Kelikian 1956
Scuderi 1991
Haas 1992
Larson 1995*

SERVIZIO SANITARIO REGIONALE EMILIA-ROMAGNA Istituto Oncologico Pascale di Bologna Istituto di Ricovero e Cura a Carattere Scientifico

ACUTE SURGICAL REPAIR

IN CASE OF INADEQUATE TISSUE

2) AUGMENTATION WITH ALLOGRAFT




- ✓ **PATELLAR TENDON**
- ✓ **ACHILLES TENDON**
- ✓ **FASCIA LATA**

SERVIZIO SANITARIO REGIONALE EMILIA-ROMAGNA Istituto Oncologico Pascale di Bologna Istituto di Ricovero e Cura a Carattere Scientifico

ACUTE SURGICAL REPAIR

IN CASE OF INADEQUATE TISSUE

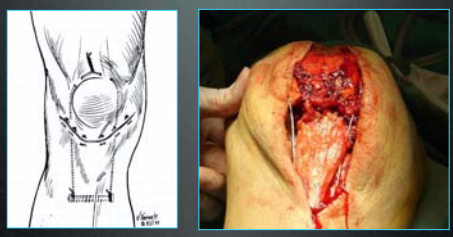
3) AUGMENTATION WITH AUTOGENOUS TISSUE COMBINED WITH ALLOGRAFT



OUR CHOICE: AUGMENTATION WITH HAMSTRINGS and ALLOGRAFT (Achilles tendon)

SERVIZIO SANITARIO REGIONALE EMILIA-ROMAGNA Istituto Oncologico Pascale di Bologna Istituto di Ricovero e Cura a Carattere Scientifico

REINFORCE WITH STEEL WIRE TO PROTECT THE REPAIR



PROXIMAL IN THE QUADRICEPS TENDON DISTAL TO TIBIAL TUBERCLE

Mc Laughlin 1947

SERVIZIO SANITARIO REGIONALE EMILIA-ROMAGNA Istituto Oncologico Pascale di Bologna Istituto di Ricovero e Cura a Carattere Scientifico

ACUTE SURGICAL REPAIR

ALTERNATIVE TECHNIQUE



AUGMENTATION WITH ALLOGRAFT (fascia lata) AND STEEL WIRE TO PRESERVE INTACT AUTOGENOUS TISSUE (HAMSTRINGS)

SERVIZIO SANITARIO REGIONALE EMILIA-ROMAGNA Istituto Oncologico Pascale di Bologna Istituto di Ricovero e Cura a Carattere Scientifico

POSSIBLE DIFFICULTIES

- ✓ **LACK OF AUTOGENOUS TISSUE**
- ✓ **QUADRICEPS CONTRACTURE AND RETRACTION OF PROXIMAL PORTION if delayed surgery (> 6 days)**
- ✓ **DIFFICULT WOUND HEALING (ematoma)**

Siwek 1981
Larsen 1986
Ramsey 1988

SERVIZIO SANITARIO REGIONALE
EMILIA-ROMAGNA
Istituto Oncologico Pascale di Bologna
Istituto di Ricovero e Cura a Carattere Scientifico



RESULTS OF PATELLAR TENDON REPAIR

EXCELLENT FUNCTION IN ACUTE REPAIR WITH OR WITHOUT AUGMENTATION

CHRONIC REPAIR LESS FAVORABLE OUTCOME

LESS MUSCULAR PERFORMANCE

Ecker 1979
Larsen 1986
Larsen 1995
Lindy 1995

Falconiero 1986
McNally 1988
Marsy 1999
Crisis 2005
Ramseier 2006


SERVIZIO SANITARIO REGIONALE
EMILIA-ROMAGNA
Istituto Oncologico Pascale di Bologna
Istituto di Ricovero e Cura a Carattere Scientifico



REHABILITATION

BRACE FOR 4 WEEKS WITH PROGRESSIVE WEIGHT BEARING

ROM 0-30° ALLOWED IN THE FIRST 2 WEEKS TO AVOID ADHESION

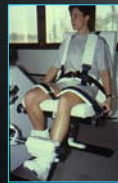

- ✓ **QUADRICEPS CONTRACTION**
- ✓ **ELECTRICAL STIMULATION**

SERVIZIO SANITARIO REGIONALE
EMILIA-ROMAGNA
Istituto Oncologico Pascale di Bologna
Istituto di Ricovero e Cura a Carattere Scientifico



INTENSIVE PROGRAM AFTER 4-6 WEEKS



SERVIZIO SANITARIO REGIONALE
EMILIA-ROMAGNA
Istituto Oncologico Pascale di Bologna
Istituto di Ricovero e Cura a Carattere Scientifico




PATELLAR TENDON RUPTURE: CONCLUSIONS

- ✓ **DEBILITATING INJURY**
- ✓ **PROMPT DIAGNOSIS ESSENTIAL**
- ✓ **DIFFERENT TYPE OF RUPTURE**
- ✓ **PREPARED TO COMBINE DIFFERENT SURGICAL TECHNIQUE**
- ✓ **LONG AND DIFFICULT REHABILITATION**

SERVIZIO SANITARIO REGIONALE
EMILIA-ROMAGNA
Istituto Oncologico Pascale di Bologna
Istituto di Ricovero e Cura a Carattere Scientifico



Thank You

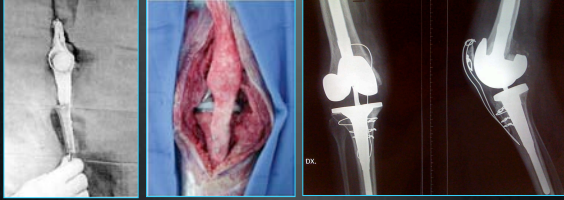


SERVIZIO SANITARIO REGIONALE
EMILIA-ROMAGNA
Istituto Oncologico Pascale di Bologna
Istituto di Ricovero e Cura a Carattere Scientifico



SPECIAL TOPIC

THE EXTENSOR MECHANISM ALLOGRAFT



**MANAGEMENT OF ACUTE PATELLAR TENDON RUPTURE IN TKA
IN CASE OF INADEQUATE AUTOGENOUS TISSUE AUTOGRAFT
(ASSOCIATE EVERY TIME THE REINFORCE WITH STEEL WIRE
TO PROTECT THE REPAIR)**

SERVIZIO DIAGNOSTICO REGIONALE
PUBBLICAZIONE
Istituto di Patologia e Cura e Carattere Specialistico

*Emerson 1994
Zanotti 1995*

